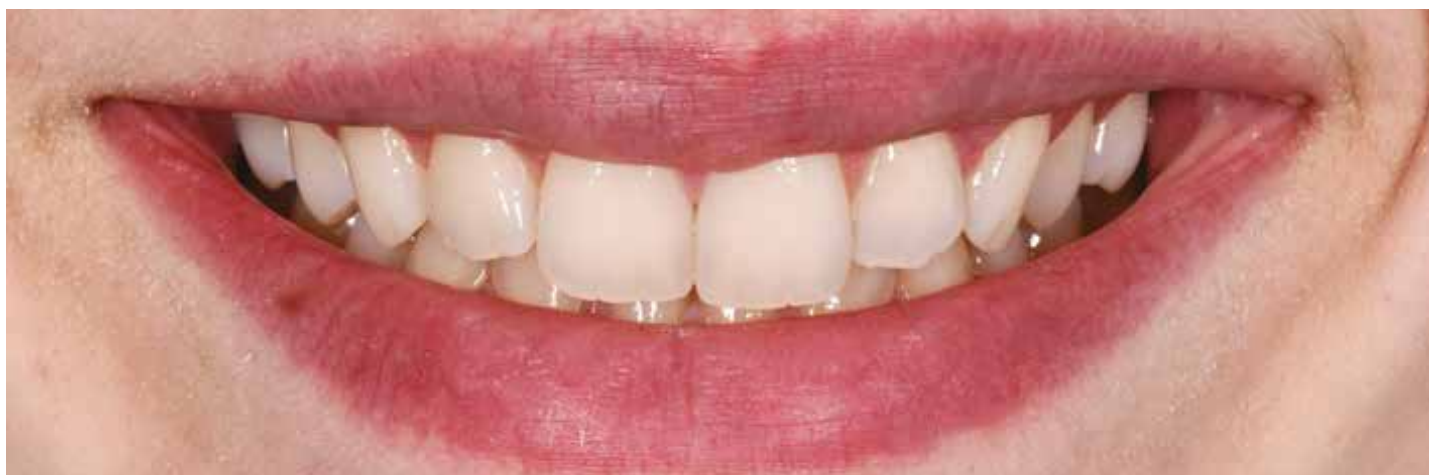

# Elastodontics: Bio orthodontics with Postural Function

Prof. dr. Lorenzo Vanini, dr. Filippo Cardarelli, prof. dr. Camillo D'Arcangelo



Prof. Dr. Lorenzo Vanini. Adjunct Professor at the University of Chieti, Visiting Professor in Aesthetic Restorative Dentistry at the De La Mediterranee University of Marseille (France), and at the Andres Bello Vinã del Mar University (Chile) for 25 years he has been carrying out research on composite materials in Italy and Germany where in 1995 he developed the Enamel Plus HFO composite system. He is an active member of the Italian Academy of Conservatives and the Italian Society of Conservative Dentistry. He is the author of numerous scientific publications, co-author of the manual-atlas "New Aesthetic Concepts in the use of composite materials" published in 1995 by the "Friends of Brugg", co-author of the manual-atlas "The conservative restoration of the posterior teeth 2" published in 2000 by the "Friends of Brugg" and author of the two-volume treatise "The conservative restoration of the front teeth" published by Acme Viterbo in 2003, of the Integrated Multimedia System "The direct composite restorations in the front teeth" of UTET, co-author of the treatise "Aesthetics, Function and Posture" of 2018" published by Acme and chapters in several books on conservation and traumatology in Italy and abroad. Speaker at internationally renowned congresses, he has held specialization courses in reconstructive dentistry at numerous universities in Europe, the United States, Chile, Argentina, Brazil, Israel and China. He practices as a freelancer in Chiasso (Switzerland) devoting himself in particular to conservation, prosthetics and posturology.



Dr. Filippo Cardarelli graduated with honors in Dentistry and Dental Prosthesis. Specialized with Honors in Orthodontics at the University of Milan. Lecturer in Pediatric Dentistry at the University of Milan until October 2019. Author of publications in national and international journals. Author of a new orthodontic technique in childhood and for adults: Elastodontic Therapy®. Speaker in Italy and abroad. Scientific director of the Amcop Micerium project in Italy and abroad. Freelancer in Isernia, Milan, Chiasso (CH), where he deals exclusively with Orthodontics and Aesthetic Dentistry. He collaborates with specialists in other disciplines to solve particularly complex cases. He collaborates with Dr. Lorenzo Vanini, in Switzerland, in the resolution of orthodontic complete cases particularly to be treated with Elastodontic Therapy®.



Prof. Dr. Camillo D'Arcangelo. Full Professor of Restorative Dentistry, Faculty of Dentistry, University of Chieti, President of SIDOC (Italian Society of Conservative Dentistry); Dean of the Clinical Unit of Restorative Dentistry and Odontics, University of Chieti; Dean of the Master of Specialization in Minimally Invasive Aesthetic Dentistry, University of Chieti; Professor of Restorative Dentistry, School of Orthodontics, School of Dental Hygiene, School of Oral Surgery, University of Chieti; Visiting Professor in many International Universities; Honorary Professor of the Ukrainian Medical and Dental Academy; Member of the Editorial Board of "Italian Journal of Endodontic" (Italy) and "Stomatology" (Poland); Reviewer di "Journal of Adhesive Dentistry", "International Endodontic Journal", "Indian Journal of Dental research", "Journal of Applied Oral Science", "International Journal of Oral Science", "Dental Materials"; Invited speaker at the most important International Congresses of Restorative, Prosthetic and Aesthetic Dentistry. He has published more than 100 articles in prestigious international journals. His clinical practice is limited to Restorative and Prosthetics.

## Occlusion and Body Posture

From scientific and clinical evidence today we know that the musculoskeletal balance of the stomatognathic apparatus also affects the musculoskeletal balance of the entire patient's body, in other words the functional disorders of the occlusion, the temporomandibular joint and the masticatory muscles can cause dysfunctions in different areas of the body, far from the mouth, such as the head, cervical area, back, pelvis, lower limbs and feet (Figure 1 to 4).

These disorders in many cases are responsible for a painful symptomatology that can affect different areas of the body and can partially or completely compromise the quality of life both from a physical and psychological point of view; this pathology defined by Vanini, D'Arcangelo and Mastroberardino "Postural Syndrome" (Fig. 5) tends over time to become chronic, establishing a posture of adaptation. If a posture of adaptation to a dysfunction is maintained over time, this adaptation can generate a deformation of the body that will tend to remain even once the element that triggered the defense adaptation has been eliminated. This compensation ends up producing tensions, twists, wear and permanent deviations that the neuromuscular system and tissues integrate into their memory and, over time, assume them as their own through repetitive and constant movements (Figures 6 and 7). The anatomical relationship between the mandible and the hyoid bone through the suprahyoid and subhyoid muscles explains how the mandibular position can interfere and condition the segmental posture of the body. The mandible, in fact, influences the position of the hyoid bone through the suprahyoid muscles. The digastric and stylohyoid muscles constrain the position of the hyoid bone to that of the jaw and head; the omohyoid muscle, in turn, inserting itself on the upper margin of the scapula inside the incisura, binds the hyoid bone to the scapula and indirectly, through the suprahyoid muscles, to the mandible. A malposition of the jaw, due to a malocclusion, therefore

determines a tension at the level of the scapula involving the elevator of the scapula. The elevator muscle of the scapula originates from the transverse processes of the first four cervical vertebrae and fits on the medial angle and in the upper part of the vertebral margin of the scapula. A laterodeviation of the jaw indirectly induces through the above-mentioned muscle chains tension at the level of the scapula elevator with consequent tension and torsion of the first cervical vertebrae. The fascial tissue, consisting of a network of thin connective tissue that connects all the organs and systems of our body, through the stimuli that come to it, is able to learn repeated postural patterns or movement constantly memorizing and stabilizing them in neural circuits.

All this translates into an adaptation of the lower segments (shoulder girdle, pelvis, lower limbs, feet) through the muscle bands and in the creation of a compensating posture that over time develops a Postural Syndrome characterized by a complex symptomatology that can affect different areas of the body.

The temporomandibular joint (TMJ) is also affected, triggering joint problems, from intracapsular tensions to disc dislocations, to degenerative arthrophic forms. A pathology of the temporomandibular joint can create ear problems with pain, roaring and tinnitus (Fig. 8). The retro discal area of the TMJ is connected to the middle ear through the Civinini canal, named after the scholar who first described it in 1830, and houses two ligaments that originate from the neck of the hammer and are inserted one at the level of the articular capsule and the other at the level of the internal jaw. A poorly placed jaw with incorrect dynamics can cause tensions at the ligamentous level that can turn into auditory stimuli (tinnitus) through the activation of the tympanic membrane. Orthodontic movements can cause TMJ problems over time and joint clicks often appear during or at the end of therapy. Every slightest movement or change in the occlusal contacts of the dental element, determines an adaptation of all the

areas of the body through the cerebral cortex that from time to time reprocesses the neuromuscular engrams and postural. A forced position of the teeth interferes with neuroplasticity by creating changes at the cortical level that disturb the natural neuroplasticity of the brain. Recent studies show that neuromuscular disorders associated with dental malocclusion should be considered as brain dysfunctions affecting the functions of the oral cavity. Changes in occlusion and cranial bones that occur during orthodontic treatment can improve oral functions through neuroplasticity. All this implies that orthodontic treatment can alter the sensorimotor behavior of the oral cavity, which is the basis of the anatomical structure of the hard and soft oral tissues (Fig. 9). This view is at odds with conventional orthodontic concepts, which consider the effects of orthodontic therapy essentially limited to the dento-alveolar structures. The restoration of occlusal and masticatory function is one of the important goals for improving the quality of life. Untreated malocclusion is significantly associated with oral health-related quality of life (OHRQoL). The more severe the malocclusion, the worse the impact on certain physical, psychological and psychosocial factors.

Brain functions such as learning and memory are reduced by the loss of associated occlusal media tooth extraction and chewing dysfunction (Fig. 10). It is believed that a variety of factors such as neurotransmission from the ligament periodontal and spindle muscle and mechanical stimulation for contact with teeth affect the relationship between occlusion and function cerebral, however, this relationship has not yet been completely clarified (Fig. 11).

## Bio orthodontics

The term Bio orthodontics refers to a new approach to orthodontic therapy in compliance with very important principles such as minimal invasiveness, respect for oral tissues and body posture and simplification of care.

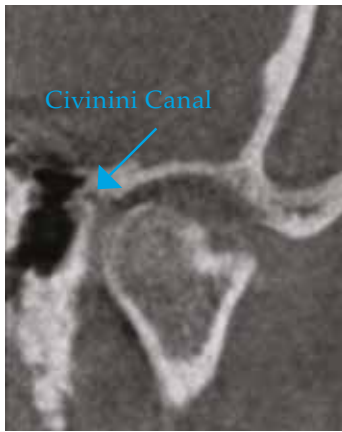


Fig. 1 ATM CT scan where the Civinini Canal is highlighted, this connects the temporomandibular joint with the cavity tympanica

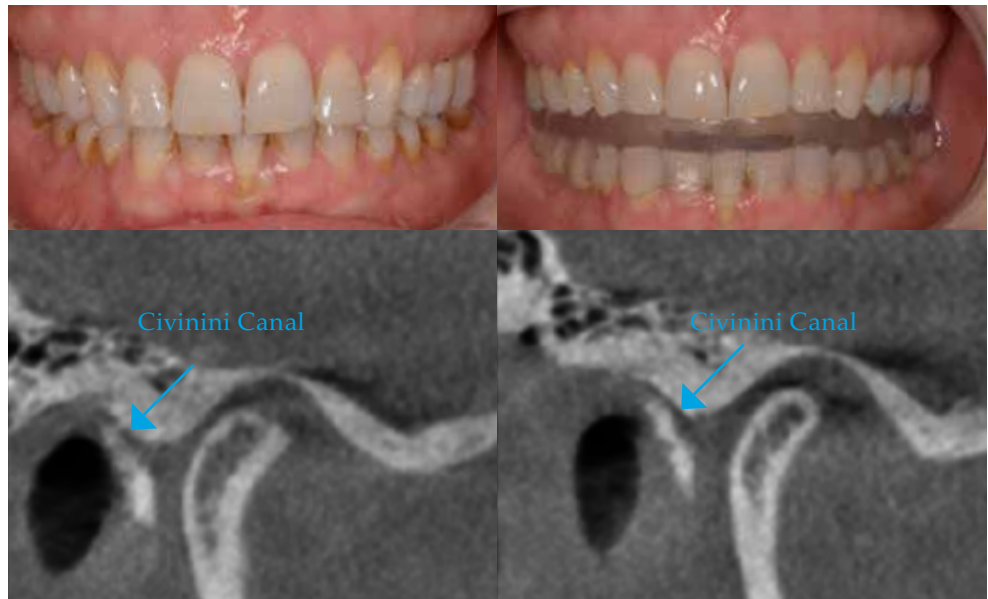


Fig. 1a A retroposed condylar position compresses the retrodiscal tissue by increasing the intracapsular tension and the differentiated fibrous structures that connect the middle ear with the TMJ which are the malleolar disc ligament (MDL) corresponding to the posterior upper fibers of the retrodiscal tissue and the anterior malleolar ligament (AML) which is an extension in the tympanic cavity of the sphenomandibular ligament that penetrate into the middle ear through the Civinini canal here clearly visible (red arrow). In the CT scan of the TMJ, the retroposed condyle in this young patient is highlighted, reports tinnitus, muffling and pain in the ear and tension in the cervical musculature and shoulder girdle.



Fig. 2 Amcop elastodontic apparatus

Fig. 1b After the application of a bite of distraction and mandibular advancement the condyle appears centered with less tension in the back-disc area

Bio orthodontics studies the correct growth of the maxillary arch mandibular and during their evolution. This interrelation is the result of a complex dynamic process, which takes place from childhood to adulthood through physiological changes, more evident during some stages of teething compared to others; everything is related to the mode of growth of the skeletal structures of the environmental influences and the process of formation and eruption of the dental elements. Knowledge of the evolutionary process of the arches and peculiarities of the development of dentition in its different stages, deciduous, mixed and permanent, it is decisive for diagnostic and therapeutic purposes, given that a skeletal malocclusion that is intercepted as soon as possible is

more quickly it is resolved (Fig. 12). During the different phases of growth are the occlusal relationship and the skeletal, functional and aesthetic parameters. Fundamental bio orthodontics has the following objectives:

- Biological success
- Minimally invasive
- Optimal aesthetics
- The achievement of an excellent occlusal ratio
- The postural rebalancing that arises from the occlusal one
- Occlusal stability over time

Bio orthodontics is therefore the "orthodontics" that drives in a natural and physiological way, bone growth by freeing it from the forces of the tongue and facial muscles and the muscles involved in the atypical swallowing that modify

natural bone growth.

All this will allow the physiological stable dental positioning in time, contrary to the traditional orthodontics that intervenes in bone growth occurred by placing the teeth in a forced way and then negatively interfering with the alveolo-root ratio.

### Elastodontics

Elastodontics is the orthodontic therapy that uses light and biological forces of elastic type to correct malocclusions in growing patients and adults, influencing growth, eliminating functional disorders and correcting the position and occlusal relationships of the teeth. Elastodontic therapy plays a role of primary importance in the context of modern dentistry. Preventive and interceptive

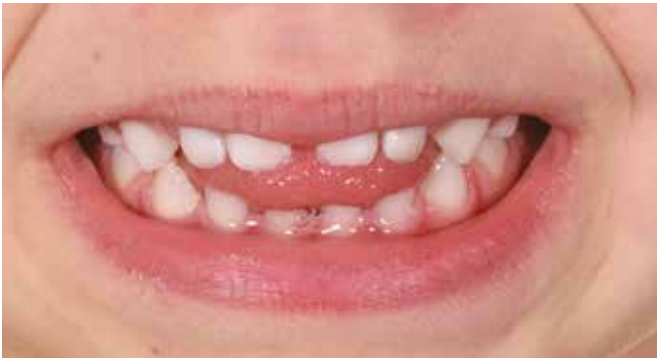

Fig. 3 Initial smile: open bite from prolonged sucking of the pacifier

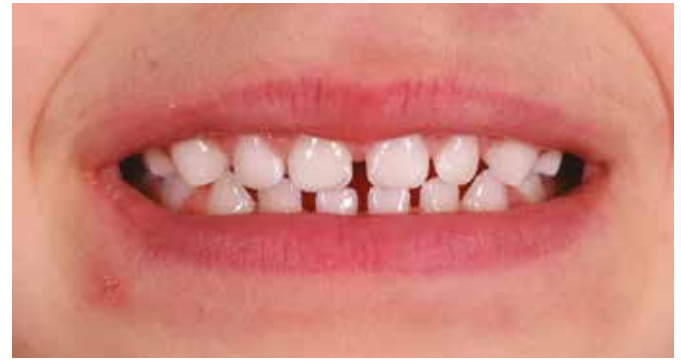

Fig. 4 Final smile: normal bite

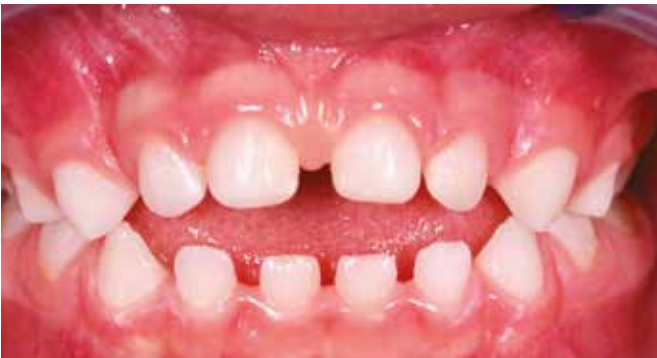

Fig. 5 Initial frontal intraoral

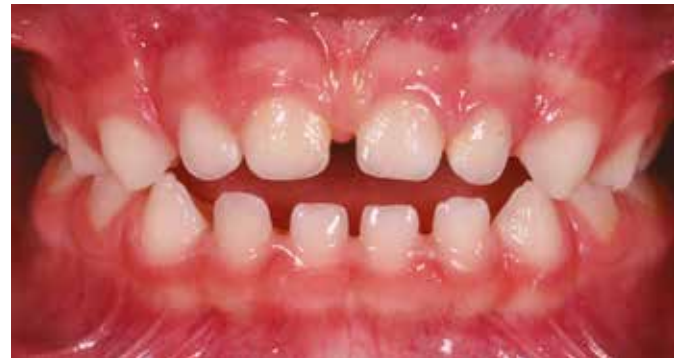

Fig. 6 Frontal intraoral at 2 months of pacifier Byte therapy

orthodontics involves treatments undertaken at an early age, during the most active stages of skeletal and dental growth, when skeletal structures are characterized by remarkable plasticity and adaptability, treatments aimed at removing the factors considered responsible for dental malocclusions (Fig. 13).

Therapy using elastodontic devices is an extraordinarily effective treatment that has multiple indications. In the treatment of children it is necessary to consider the totality of the changes, depending on the skeletal or dental problems; it therefore follows that careful analysis and adequate planning are essential (Fig. 14).

### Open bite from protracted sucking of the pacifier

3 year old Patient.

The therapeutic sequence includes the following steps (Fig. 3 to 10):

- Elastodontic therapy with byte

pacifier for about 6 months.

- Replacement of the pacifier with an elastodontic contention device

The main features that allow you to differentiate the elastodontic therapy from other orthodontic therapies are represented in the following points:

- The development of the Elastodontic Therapy is considered a very important step forward in the field of preventive orthodontics, since it can solve most (90%) of orthodontic problems quickly and easily controllable, as well as to transform most of these cases in occlusions ideal from a functional and aesthetic point of view, that do not require additional orthodontic treatments.
- In those cases where intervention occurred late with respect to the growth of the individual, elastodontic therapy will have its

results that will be complemented by a possible multibracket therapy (fixed orthodontics), in a short time of a few months.

- The orthodontic philosophy has almost always been to correct malocclusions only at the time when the complete eruption of most permanent teeth had occurred. Most of the problems of malocclusions, however, develop in the transition phase from deciduous to mixed dentition, during the eruption of the upper and lower permanent incisors; it is therefore very important an early intervention of the orthodontist through elastodontics in such a way as to eliminate early problems such as crowding, wrong molar and canine ratio and articular, skeletal and postural problems.
- Unlike traditional orthodontic techniques such as aligners that aim to align teeth without

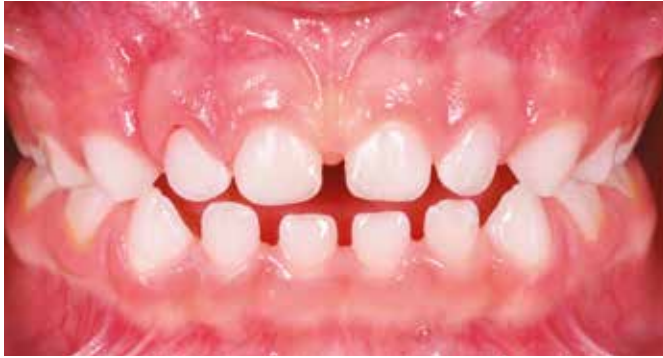

Fig. 7 Frontal intraoral at 6 months of therapy and passage to Amcop Open bite device

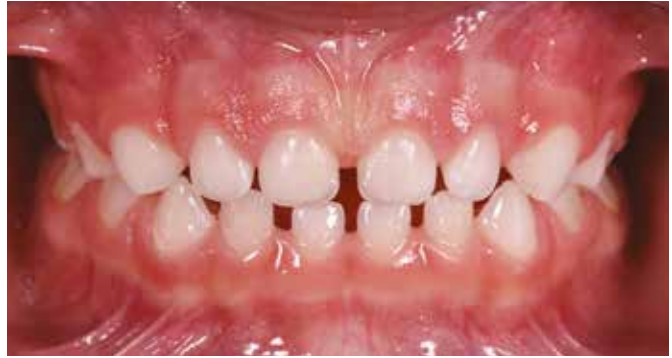

Fig. 8 Frontal intraoral at 12 months of therapy: normal Bite



Fig. 9 Bite pacifier elastodontic apparatus (Amcop)

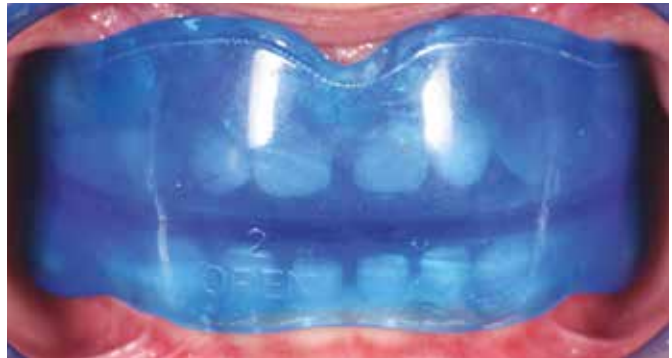

Fig. 10 Amcop open appliance

function and above all without stability over the years, elastodontic therapy has as main objective the function which will be responsible for the correct dental alignment which is, functional and stable over time.

- Standard diagnostic protocol provides documentation represented by study models, radiographic examinations (orthopantomography and radiography), cephalometric tracing with the relative measurements, photographic examination according to a protocol specific, intraoral and extraoral clinical examination, verification of the presence of any bad habits and kinesiographical examination.
- This protocol is valid for patients who are aged about 6 years old, for patients aged 3-4 years old, the protocol requires a simplified procedure through intraoral and extraoral photographic

examination, intraoral and extraoral clinical examination. Achieving an excellent result will therefore depend on a correct diagnosis and the appropriate choice of device in addition to the collaboration from the young patient.

**Malocclusion of III Class skeletal, and dental reverse front bite**

3-year-old Patient. This type of malocclusion also exists in parents. The treatment plan involves the use of an elastodontic device, to be carried for one hour during the day and all night for the first 6 months and then for a further 10 months only at night. At a later time, the resolution of the skeletal problem is kept under control with visits every six months in order to be re-intervened if the problem should reoccur. (Fig. from 11 to 18).

**Elastodontic Devices**

Elastodontic devices AMCOP by Micerium can be prefabricated or customized, i.e. made directly on the patient's mouth after performing the appropriate assessment on the corrections to be made. Their great advantage is in the fact that, unlike the classic orthodontic appliances that have an action only on the teeth, these can act three-dimensionally through a movement that simultaneously affects the bone base, dental elements and the posture of the patient. Their design, simplified home management and rapid resolution of malocclusion make them currently the most appreciated devices by patients.

**Features**

- Align teeth
- Promote mandibular and maxillary growth
- Determine a correct arch shape

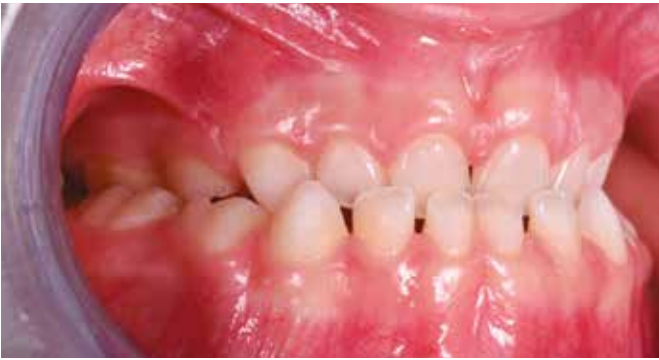

Fig. 11 Right lateral intraoral

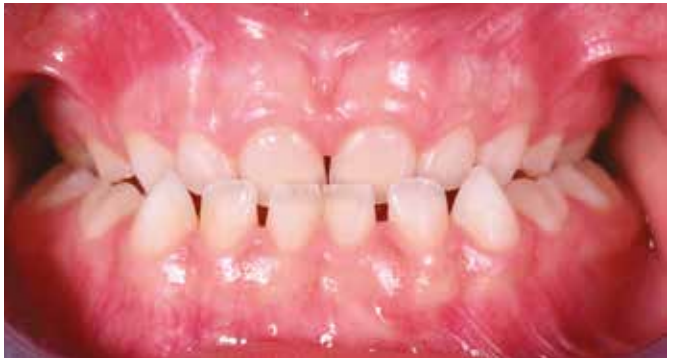

Fig. 12 Frontal intraoral

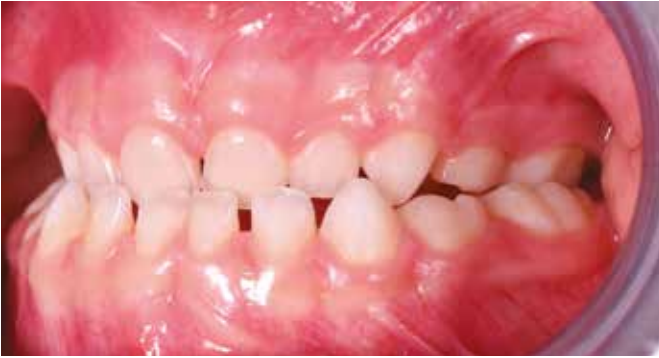

Fig. 13 Left lateral intraoral

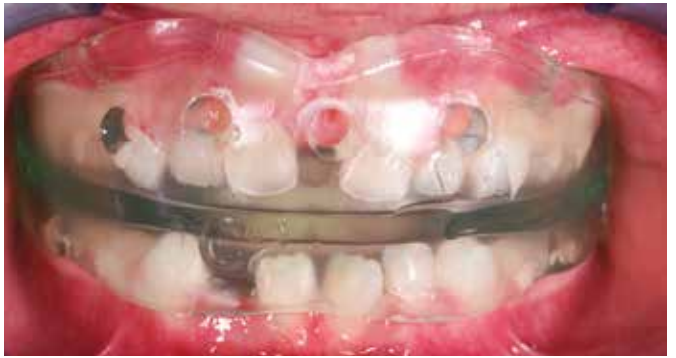

Fig. 14 Class III elastodontic apparatus (Amcop TC)

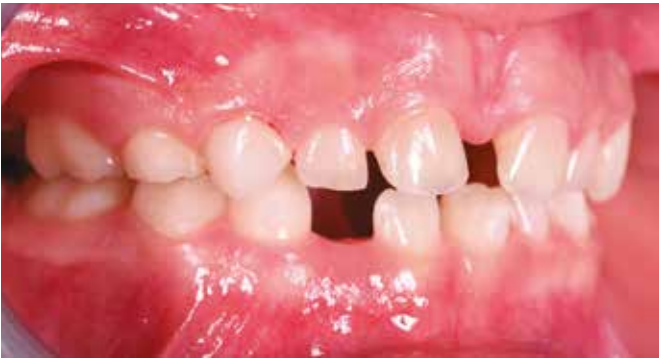

Fig. 15 Right lateral intraoral at the end of therapy

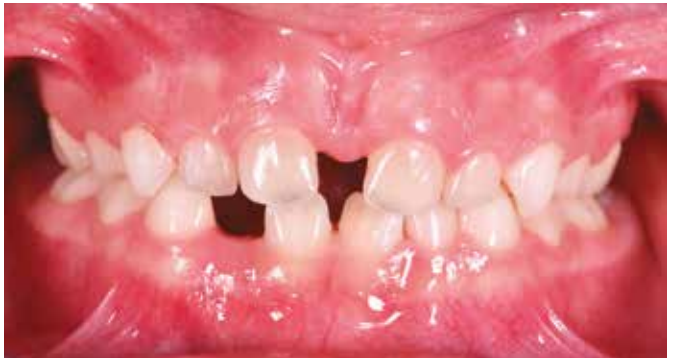

Fig. 16 Frontal intraoral at the end of therapy: resolution of the Class 3 and superior arch expansion

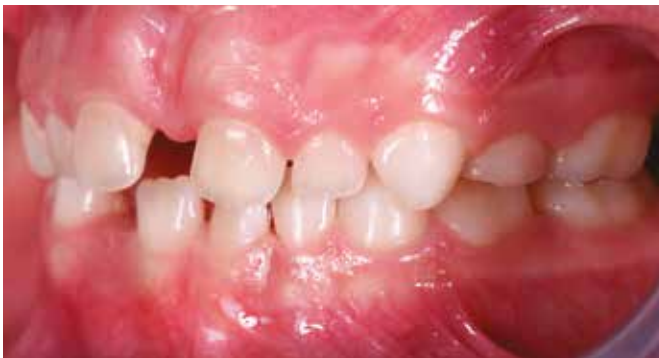

Fig. 17 Left lateral intraoral at the end of therapy



Fig. 18 Elastodontic appliance

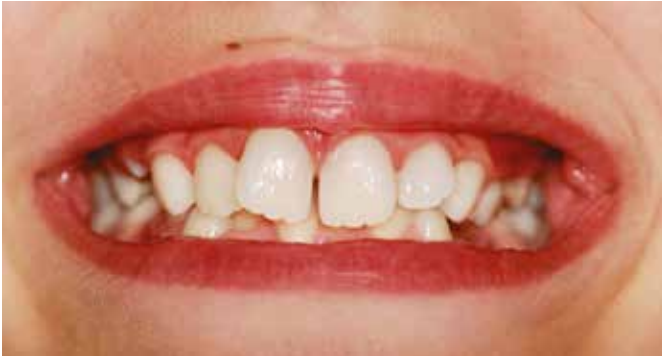

Fig. 19 Initial smile

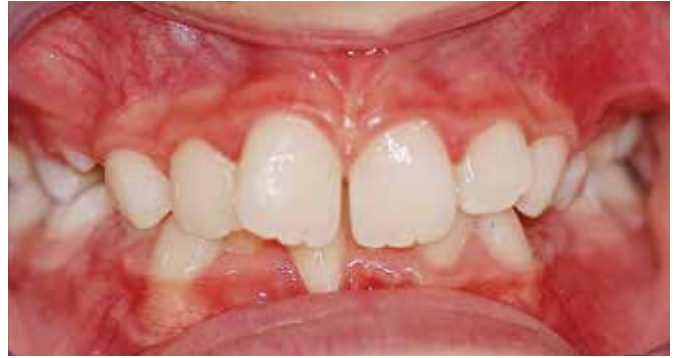

Fig. 20 Frontal intraoral: lower crowding and periodontal damage at the level of 41 due to reduced vertical dimension and occlusal trauma

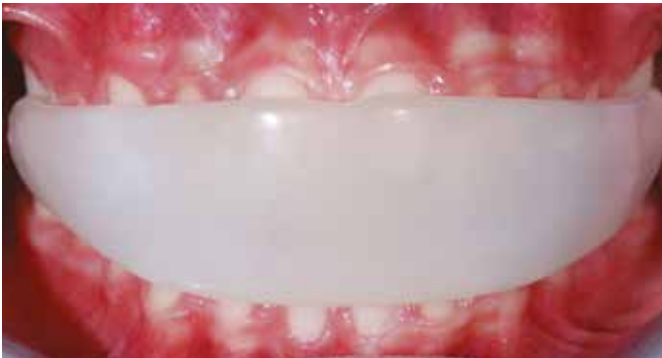

Fig. 21 Elastodontic appliance with plane chewing plate

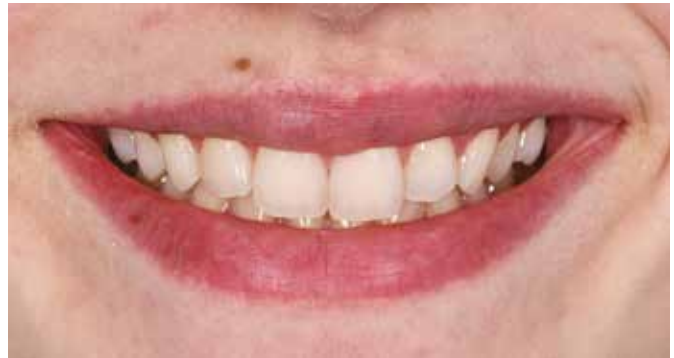

Fig. 22 Smile at the end of elastodontic therapy

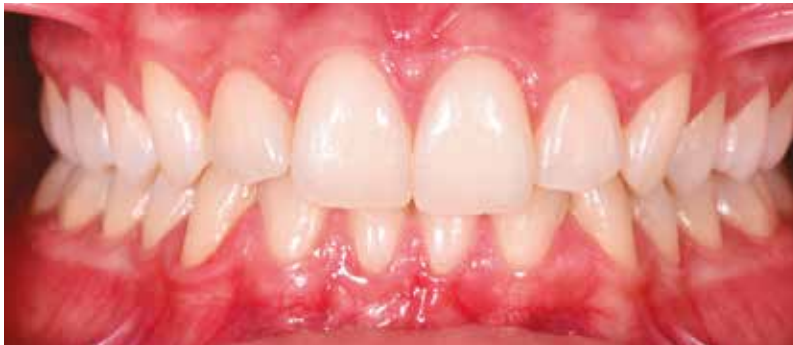

Fig. 23 Intraoral at the end of therapy: restoration of vertical dimension and resolution of dental crowding with periodontal healing

- They are ideal for all malocclusions
- Create a stable occlusion over time
- Allow you to work in harmony with body posture
- Reduce relapse
- Reduce the use of extractions

**9.5 year old Patient who has a Class II malocclusion skeletal and dental, deep bite, dental crowding**

Malocclusion is the cause of the periodontal problem of the lower incisor. Skeletal and dental

malocclusion is also associated with postural problems as can be seen from radiography, which shows compression of the first cervical vertebrae with an increase in the cervical curve created by the posterior slipping of the jaw.

Therapy through elastodontic devices allows the recovery of the vertical size and restoration of the correct arch shapes; the duration of therapy is about 18 months with retention that always takes place with the same device for another 7-8 months.

Currently, 10 years after the therapy, we can verify great occlusal stability is found. The resolution of skeletal and dental malocclusion is associated with a clear recovery of posture with consequent improvement of the cervical curve, as can be seen in the final radiography. Once the correction of the molar and anterior ratio has been obtained, the device will be worn by the patient only at night to stabilize the result obtained and guide the eruption of the permanent dental elements (Fig. 19 to 31)

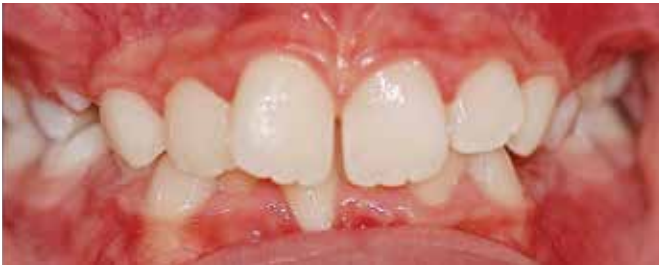

Fig. 24 Initial intraoral

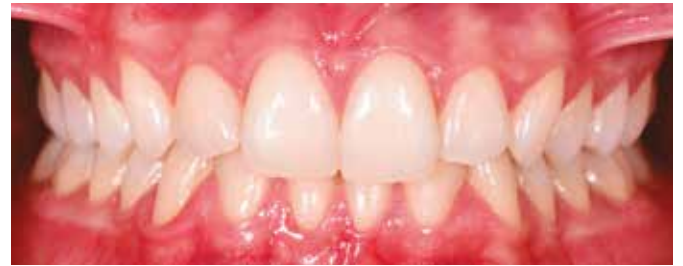

Fig. 25 Final intraoral

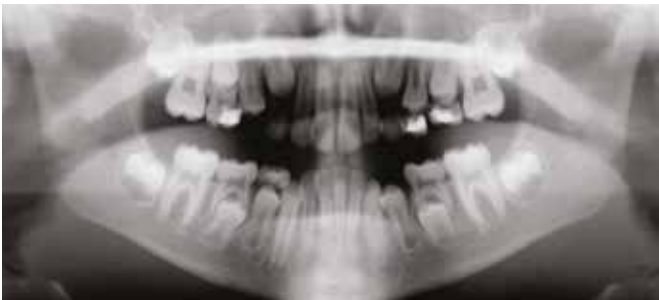

Fig. 26 Initial orthopantomography

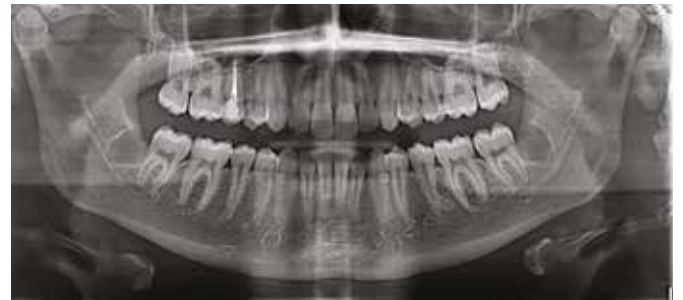

Fig. 27 Final orthopantomography

Fig. 28 initial radiography with evident mandibular retrusion and compression of cervical vertebrae

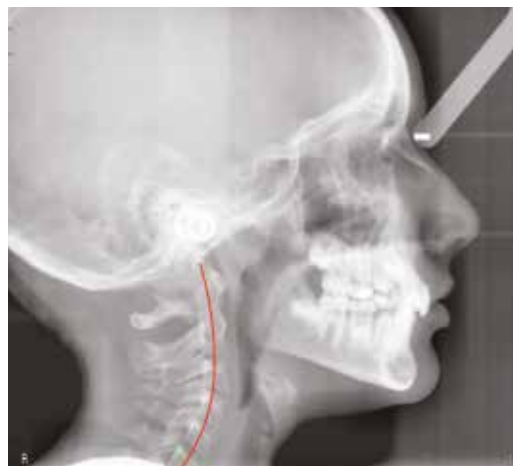


Fig. 29 final radiography with recovery of the mandibular position and resolution of the cervical curve

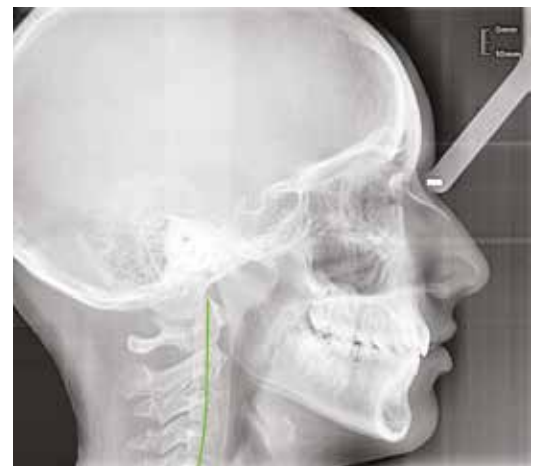

Fig. 30 Detail of the initial tele radiography that shows the reduction of intervertebral space between C2-C3

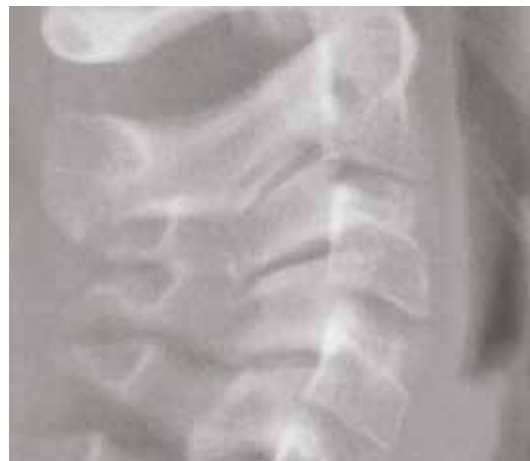
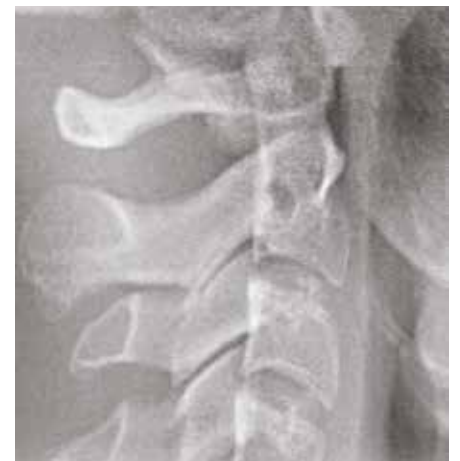
Fig. 31 Detail of the final tele radiography that shows the increase in intervertebral space





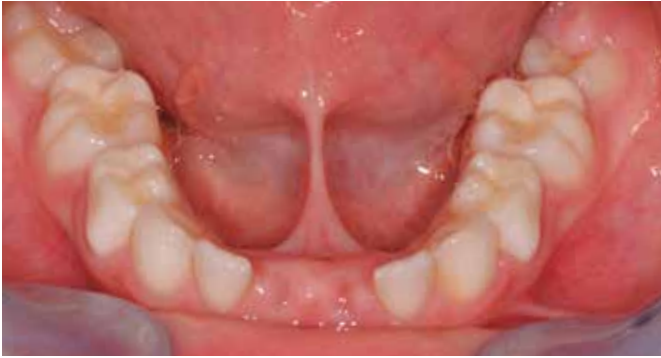

Fig. 32 Short lingual frenulum, low position of the tongue and hypomobility

### Speech therapist and orthodontist: who to look after?

The tongue is an organ that participates in many functions, some of which are not yet fully understood: food intake, chewing, swallowing, phonation, and moreover, most importantly, it represents the growth matrix already during intrauterine life, around which the surrounding anatomical structures grow and mature. It is an organ that directly affects the mandibular, the maxillary growth and morphogenesis of the dental arches. In addition, the aesthetic appearance of the face and skull can also be affected in its physiognomy by the inappropriate functioning of the groups of muscles concerned (Fig. 15). The speech therapist is the health professional who deals with the prevention, evaluation and treatment of disorders of language, communication and oral functions, in all age groups. During a twenty-four hours period, we swallow on average between 1500 and 2000 times, usually every half minute during wakefulness and every minute during sleep, we can well understand the decisive role that the tongue has in the context of the mouth and posture (Fig. 32).

### Open Bite

7 years old Patient open dental bite and skeletal from habit (protracted thumb sucking) combined with a short lingual frenulum. Malocclusion

is characterized by contraction of the upper arch with reduced space for the eruption of the permanent teeth.

The therapeutic sequence includes the following steps (Fig. from 33 to 39):

- motivation
- speech therapy
- lingual frenulectomy + speech therapy
- elastodontic therapy
- elastodontic restraint for about 12 months

### But what are the oral functions?

There are 3 oral functions and include:

- breathing
- feeding (thumb sucking, chewing, swallowing)
- language

All these functions are closely related to each other as they are performed by the same organs. Breathing is one of the fundamental prerequisites for a correct growth of the maxillofacial skeleton. Sucking, chewing and swallowing are strongly affected by lingual posture by all other facial and mouth muscles. An harmonious development of the musculature of the orofacial area will not only allow the proper performance of all functions, but also ensure healthy growth of bones and teeth.

Their balance, however, can be easily threatened by a large number of

factors: postural alterations, incorrect eating habits, malocclusions, bad habits (finger in the mouth, pacifier and protracted bottles, onychophagia), pathological conditions (enlarged adenoids and tonsils, otitis, etc.). All these alterations determine dysfunction, affecting the shape and development of the orofacial system and dental arches. Another thing to consider when talking about language is the lingual frenulum which, like the labial one, consists of connective tissue but, unlike the labial one, contains elastic fibers. The short frenulum generates a traction on the tongue making it assume a posture directed downwards and forwards, not allowing it to lie at the level of the retro incisive papilla and the Palatine Spot. The relationship between a short lingual frenulum and defects in the cervical spine and overall posture is known.

### Orthodontics today

A modern orthodontic treatment must pursue an ideal and harmonious alignment of the teeth guided by the growth of the jaws to obtain not only an excellent aesthetic result but occlusal and functional stability. The orthodontic path must also be in harmony with the postural development of the child. We are therefore talking about a team therapy where the orthodontist will intervene on the dental and skeletal system, restoring the relationships between bones and teeth stabilizing them through elastodontic treat-

Fig. 33 Image of the patient's finger responsible for the bad habit

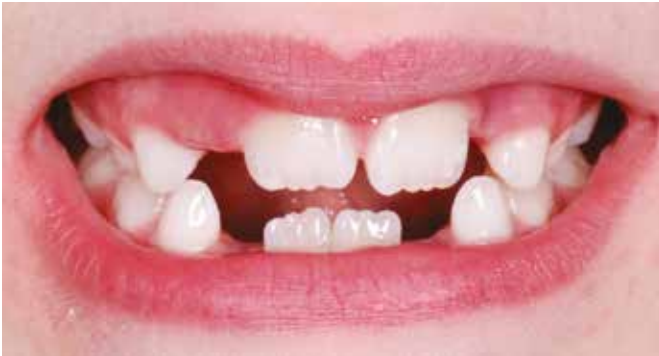
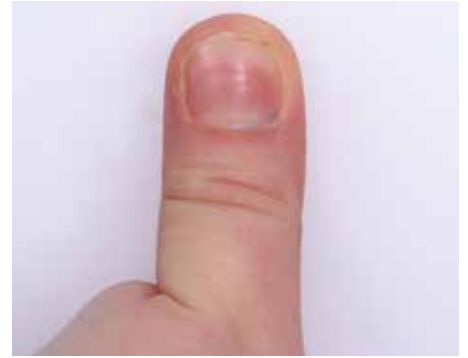
Fig. 34 Initial smile: open bite

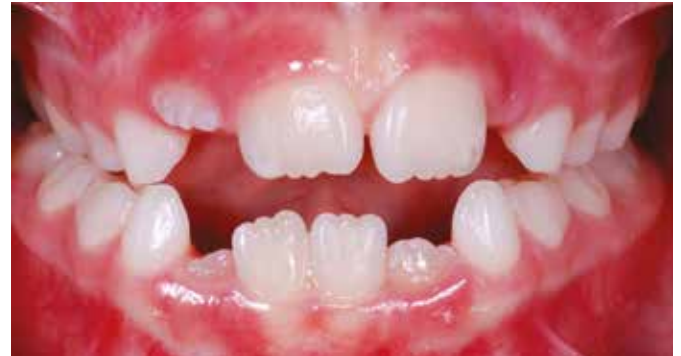

Fig. 35 Initial frontal intraoral: open bite

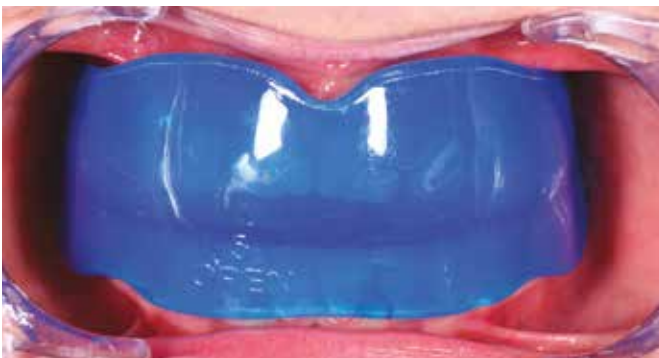

Fig. 36 Amcop Open elastodontic appliance

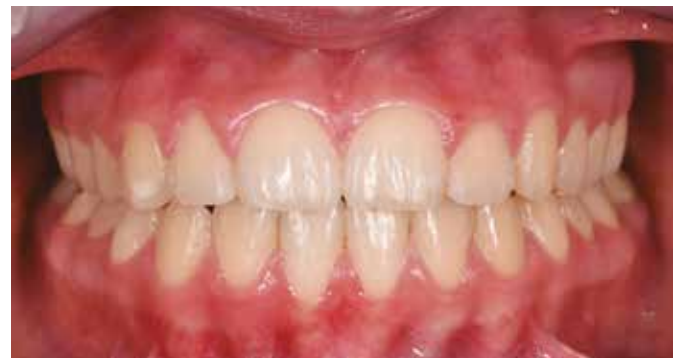

Fig. 37 Final frontal intraoral: normal bite

Fig. 38 Initial radiography with evident curve altered vertebrae

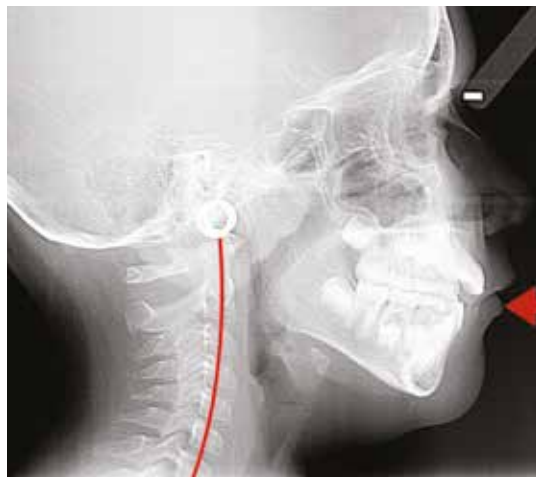


Fig. 39 radiography final with evident Cervical recovery cervical

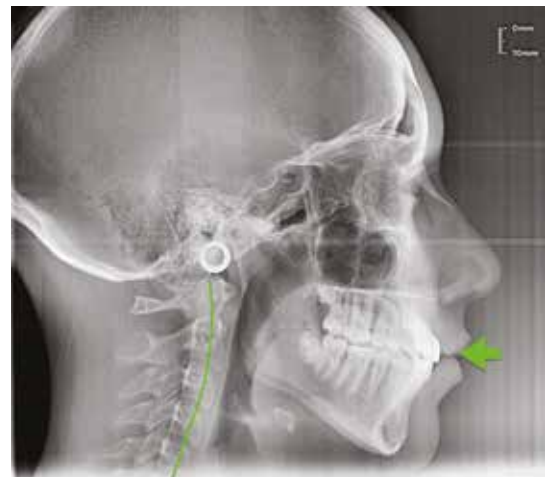



Fig. 40 Extraoral frontal

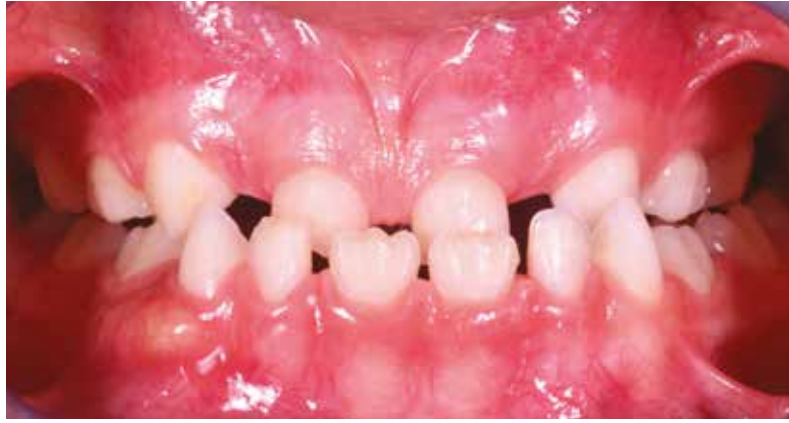

Fig. 41 Frontal intraoral: Class III

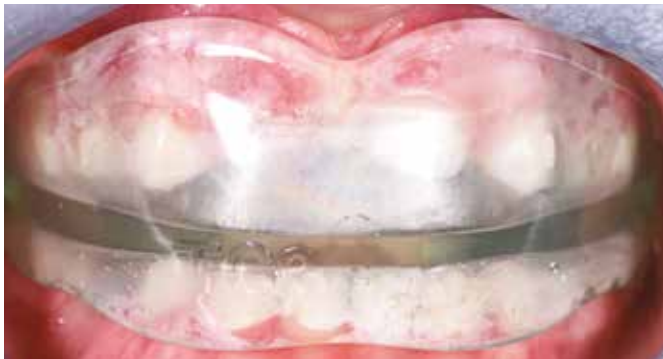

Fig. 42 Amcop CT elastodontic appliance

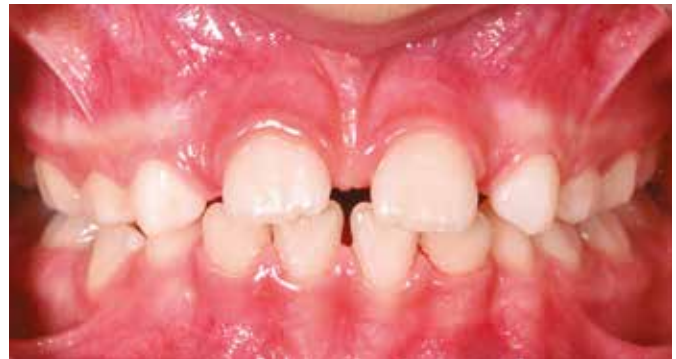

Fig. 43 Frontal Intraoral: Class I

ments, the gnathologist will control the occlusal contacts, the speech therapist will intervene on the neuromuscular component linked to the posture of the tongue with the aim of restoring the order and balance of the oro-facial structures and obtaining more lasting orthodontic results and the osteopath will watch over the balance postulate of the patient that it must be in harmony with the changes determined in the mouth by orthodontic therapy.

**5-year-old patient with anterior reverse bite**

Malocclusion is characterized by contraction of the upper arch with reduced space for the eruption of permanent teeth. The therapeutic sequence includes the following steps (Fig. from 40 to 49):

- motivation
- speech therapy
- elastodontic therapy
- elastodontic retention for about 12 months

It is evident from the initial and final radiography the resolution of malocclusion and postural problems through elastodontic therapy.

**Orthodontics, Occlusion and Posture**

Malocclusions are often a causative factor of many osteoarticular pathologies, in fact the masticatory muscles are part of the so-called "postural chain". Several studies show that the skeletal Class II is often associated with an advanced posture and hyperlordosis of the cervical spine, while the Class III is

mostly associated with a retrognathic posture (Fig. 16). Through a careful analysis of the patient's posture, from the simple clinical examination to the latero-lateral radiography of the skull, it is possible to observe the correlation between malocclusion and significant postural alterations, but also the correlation between orthodontic therapy and cervical postural effects.

With the achievement of normal occlusion through elastodontic therapy, it will also be possible to correct the patient's posture; in some cases to speed up and improve the therapy sessions of physiotherapy or osteopathy are useful. Elastodontic therapy shows great postural benefits, correcting both the occlusal planes and the cervical posture.

From a clinical point of view, the

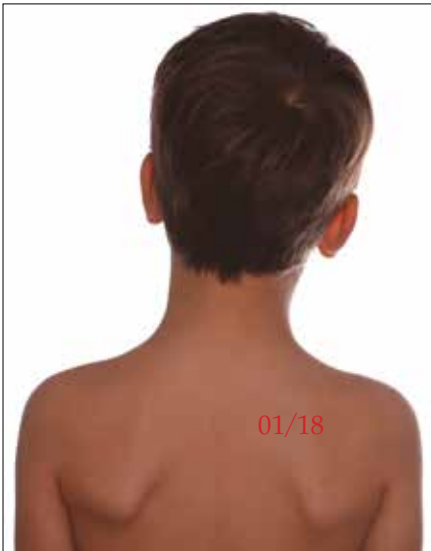

Fig. 44 Postural alteration evident from the different position of the shoulder blades

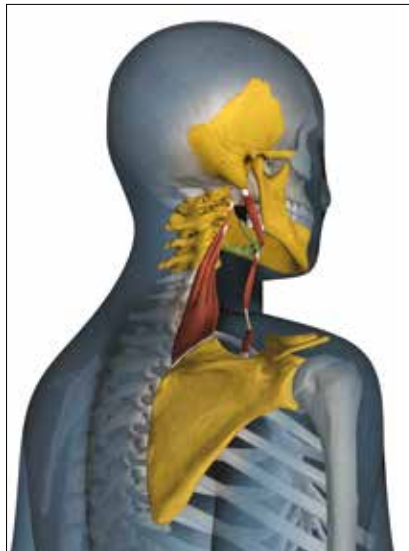


Fig. 45 Three-dimensional image which highlights the close anatomical correlation between mandible, bone hyoid and scapula

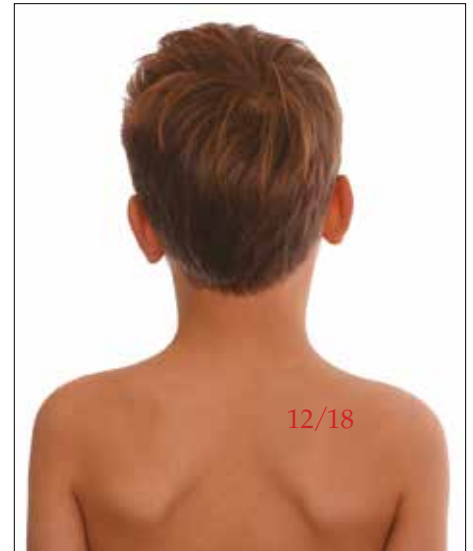

Fig. 46 Image of the back which highlights the postural benefit that results from functional elastodontic therapy

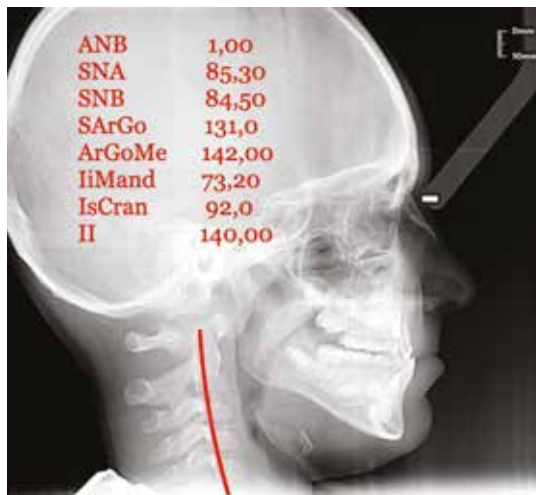


Fig. 47 Initial radiography with evident inversion of the cervical curve

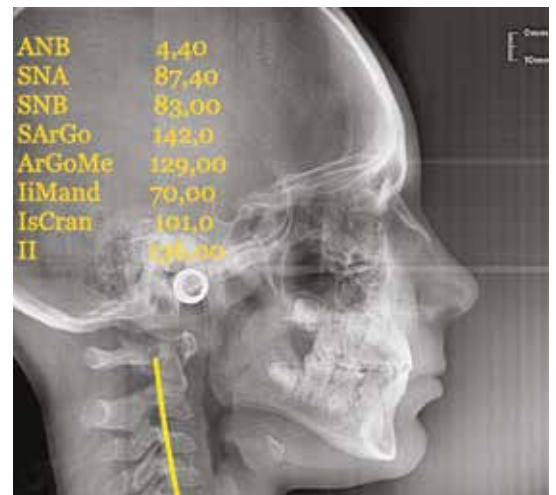


Fig. 48 radiography at 1 year of elastodontics therapy: clear improvement

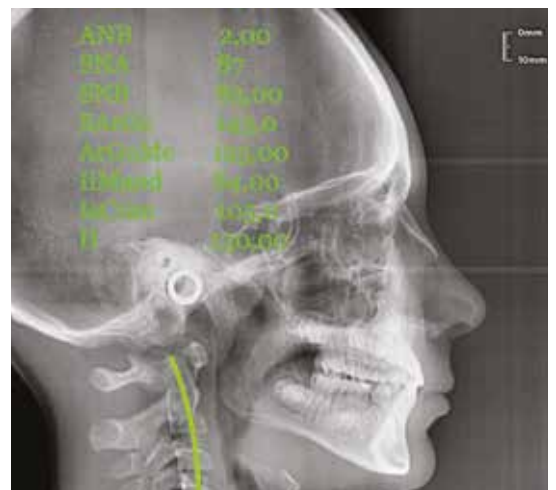

Fig. 49 radiography at 2 years: postural recovery with restoration of the normal cervical curve

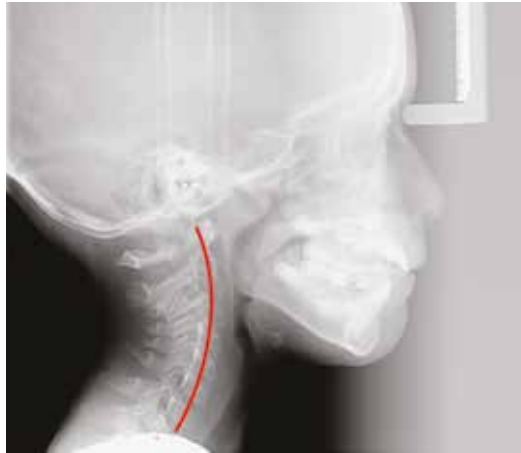
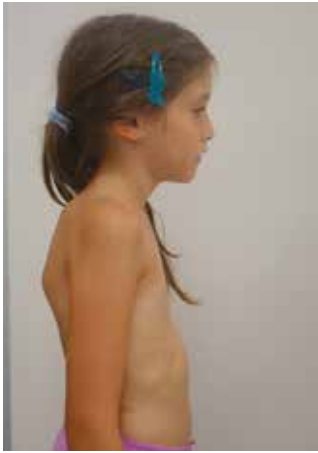
Fig. 50 Posture image of the patient suffering from open bite skeletal and dental

Fig. 51 Initial radiography from which you can see the post mandibular rotation and consequent compression of the cervical vertebrae

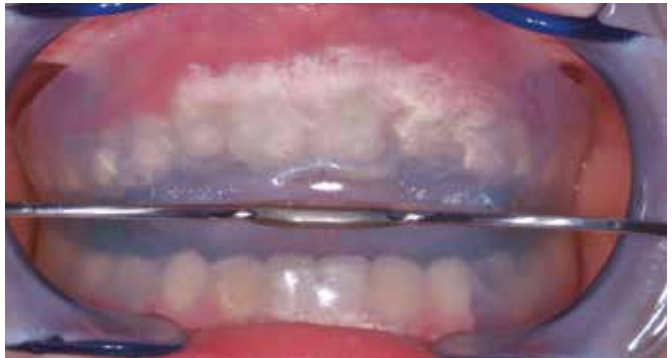
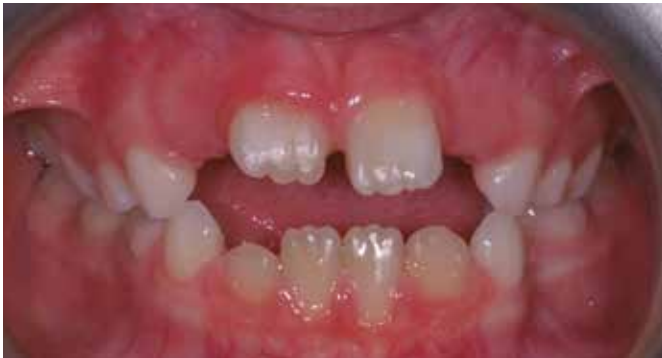
Fig. 52 Intra oral frontal: open bite

Fig. 53 Elastodontic appliance combined with Extraoral traction

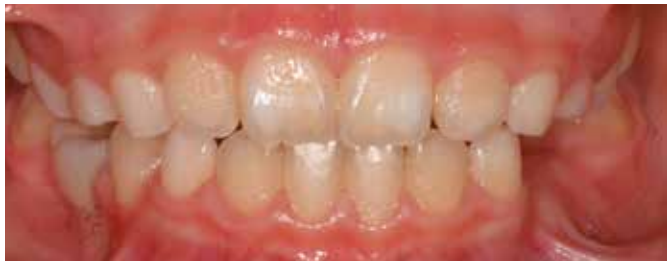
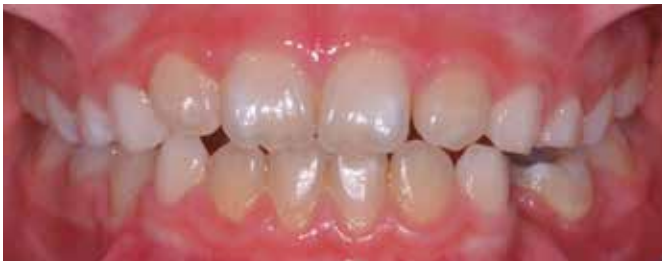
Fig. 54 Frontal intraoral at 7 months of therapy

Fig. 55 Frontal intraoral at 24 months

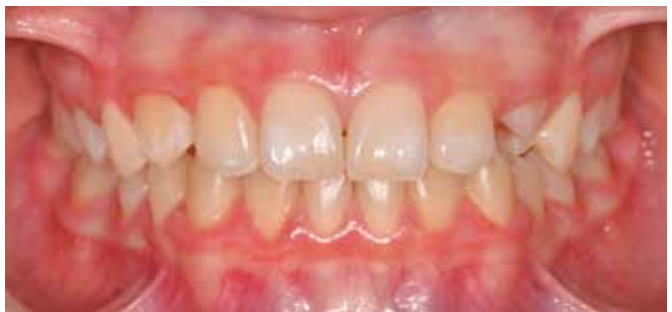
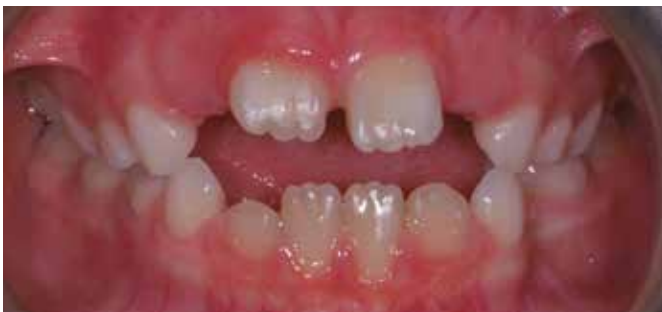
Fig. 56 Initial intraoral

Fig. 57 Intraoral control post elastodontic therapy

only way to establish whether a muscular and postural balance has been achieved is by performing kinesiological tests on the patient. Kinesiology is used in various

medical specialties and must be known and have widespread use also in dentistry.

**8-year-old open bite skeletal and anterior dental patient**

Malocclusion is characterized by contraction of the upper arch with

MAY  
2016

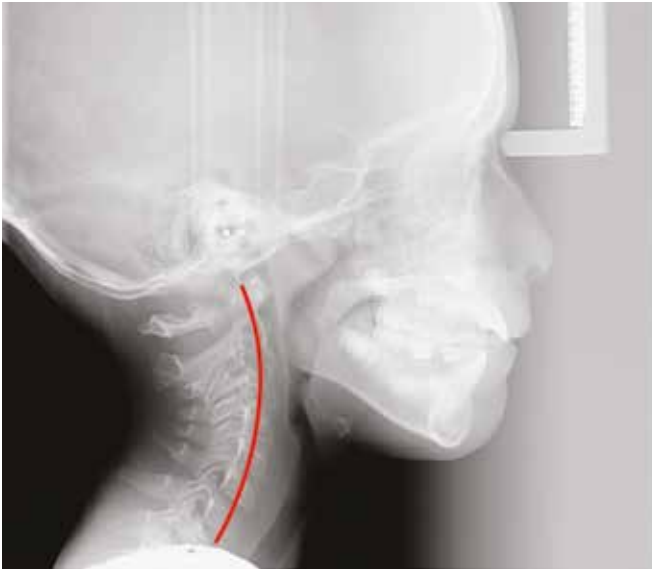


Fig. 58 Initial radiography with evident Cervical compression

NOVEMBER  
2020

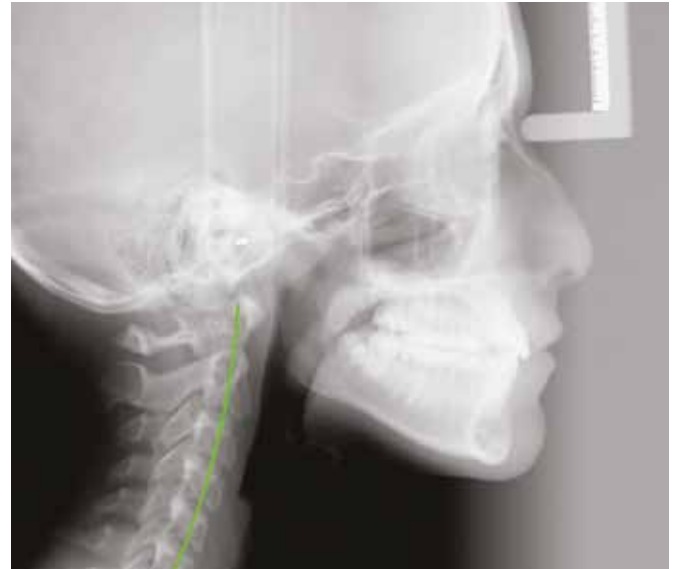

Fig. 59 Final radiography with improvement of the intervertebral space

MAGGIO  
2016

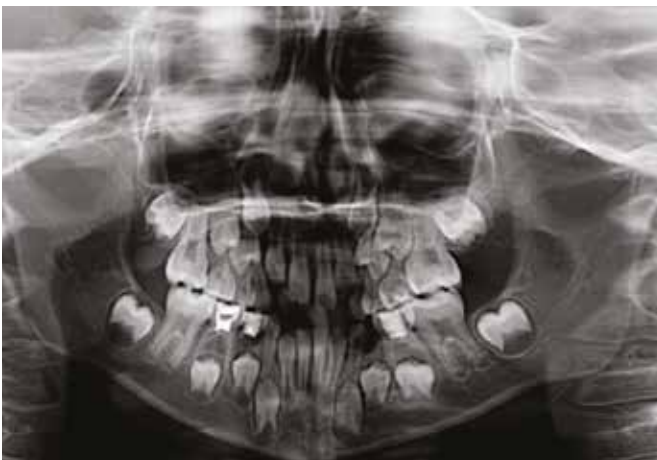

Fig. 60 Initial orthopantomography: evident contraction of the superior arch

NOVEMBER  
2020

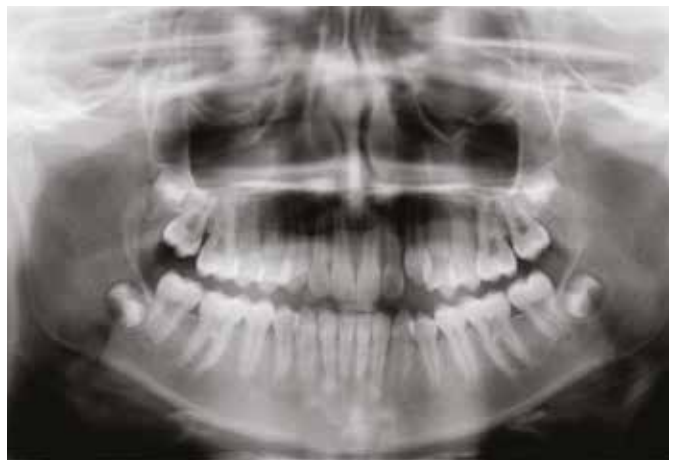

Fig. 61 Orthopantomography at the end of therapy: recovery of the physiological space of the dental elements

reduced space for the eruption of permanent teeth.  
The therapeutic sequence includes the following steps (Fig. 50 to 57):

- motivation
- speech therapy
- elastodontic therapy

- elastodontic retention for about 12 months

**6 year old patient - Severe skeletal and dental class III**

Malocclusion is characterized by

contraction of the upper arch with anterior inversion. The therapeutic sequence includes the following steps (Fig. from 58 to 67):

- speech therapy
- elastodontic therapy Class III

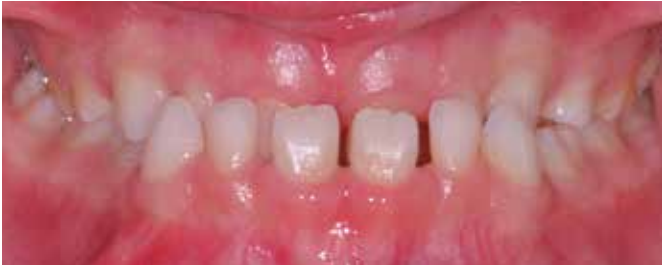

Fig. 62 Frontal intraoral: severe skeletal and dental Class III

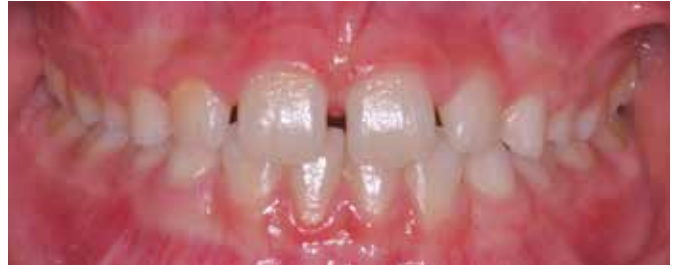

Fig. 63 Resolution of malocclusion at 12 months of elastodontic therapy

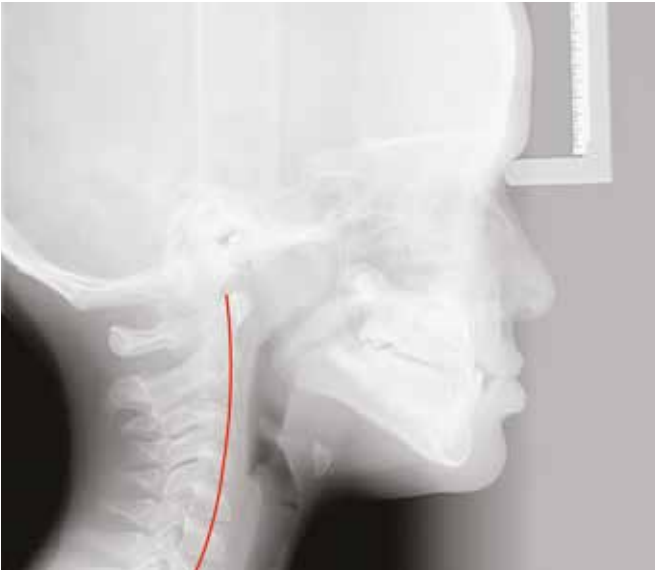


Fig. 64 Initial radiography with evident reduction of intervertebral spaces

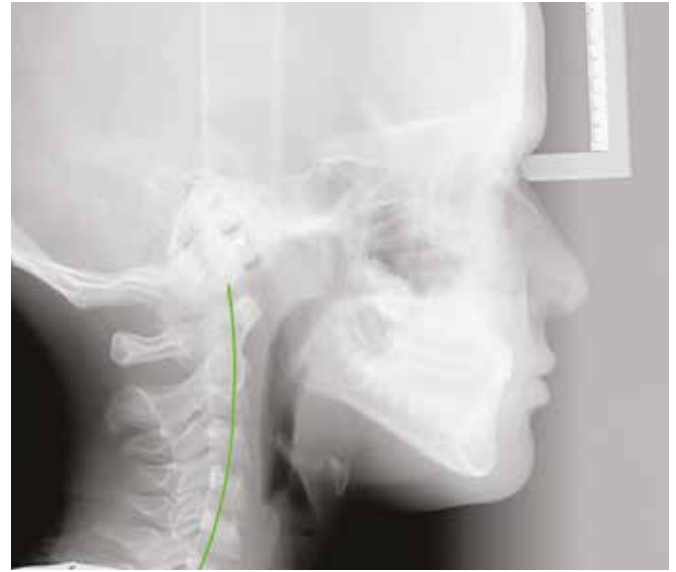

Fig. 65 Final radiography with cervical recovery

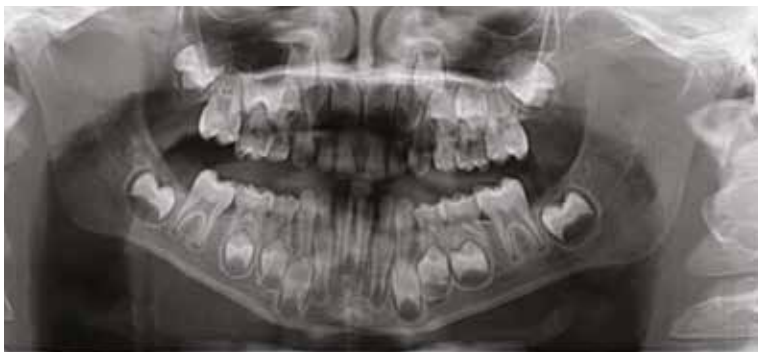

Fig. 66 Initial orthopantomography: contraction of the upper arch with space reduction for the correct eruption of the upper permanent incisors

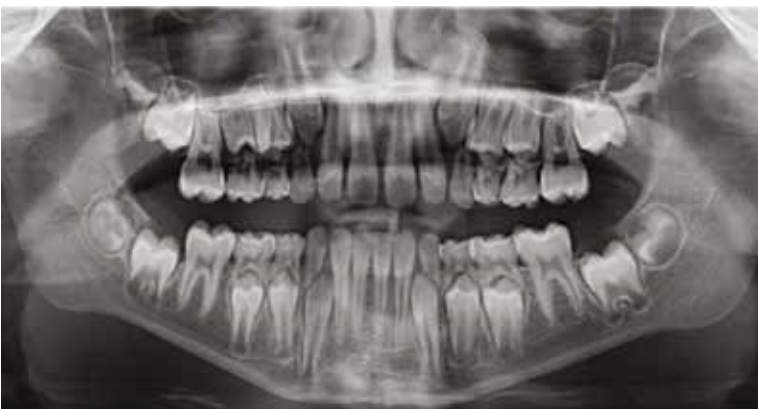

Fig. 67 Orthopantomography at the end of therapy: recovery of transversality and correct dental positioning. From the initial and final examination of orthopantomography the expansion produced from the elastodontic appliance and the subsequent alignment, as a result of the function

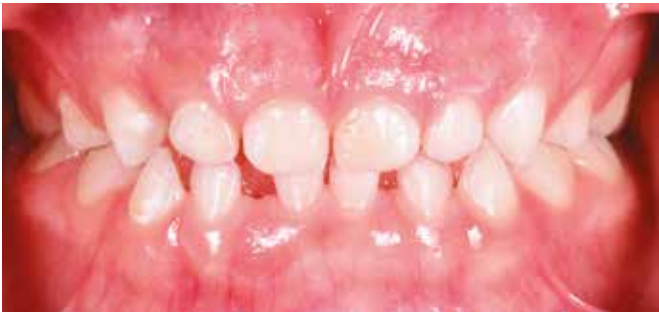

Fig. 68 Initial frontal intraoral

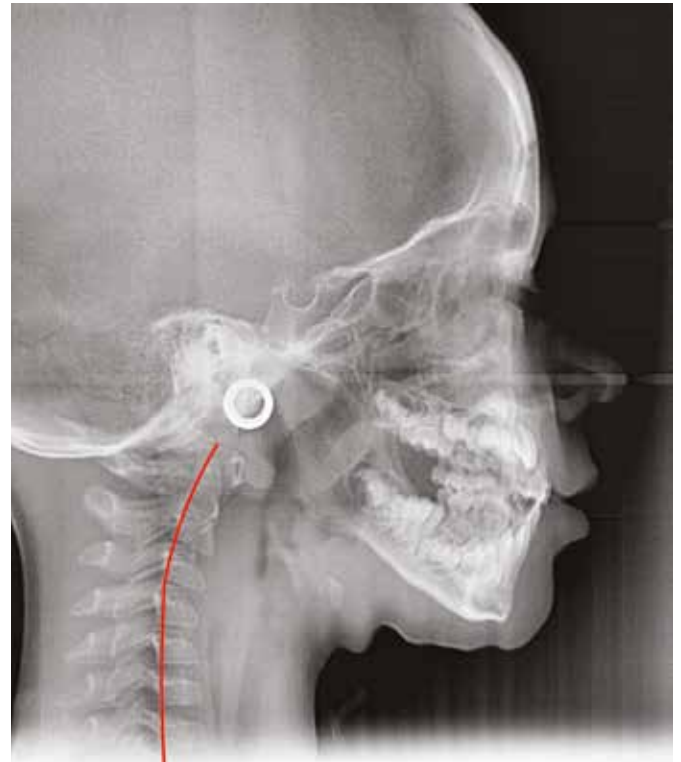


Fig. 69 Initial radiography with inversion of cervical care: Malocclusion Class III skeletal of hereditary origin

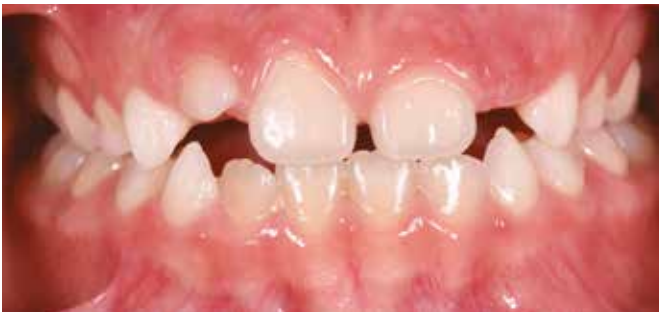

Fig. 70 Frontal intraoral during elastodontic therapy with Amcop TC device

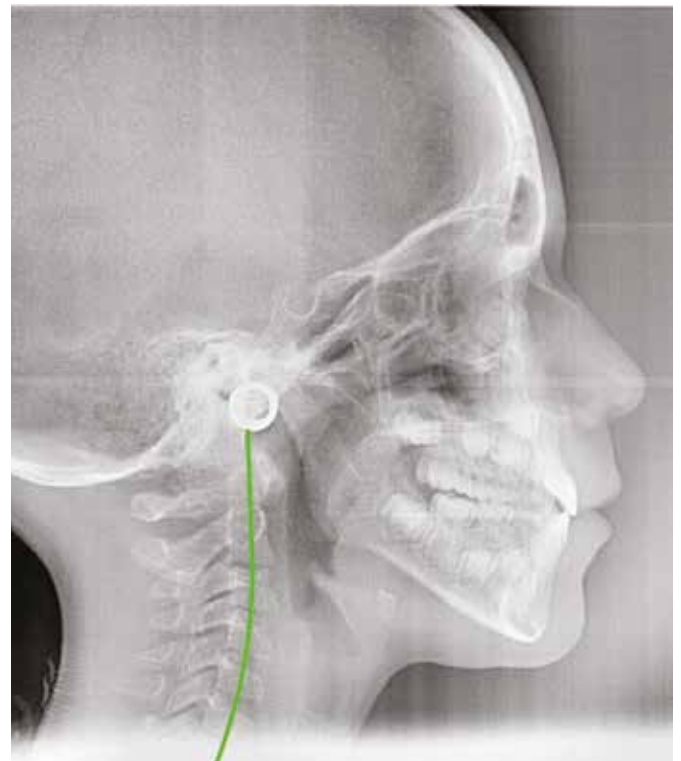


Fig. 71 radiography at 1 year of therapy with evident recovery of the cervical curve and restoration of the correct baseline ratios

- elastodontic retention for about 18 months

**5-year-old patient anterior reverse bite**

Malocclusion is characterized by contraction of the upper arch with reduced space for the eruption of

the permanent teeth. The therapeutic sequence includes the following steps (Fig. 68 to 71):

- motivation
- speech therapy
- Class III elastodontic therapy
- elastodontic retention for about 12 months

**Conclusions**

The aim of this work is to demonstrate the importance of orthodontic treatment through elastodontics in order to simplify the therapy of malocclusions and reduce any recurrences and complications. Elastodontic therapy can solve



malocclusions in a physiological way without resorting to extractions, exploiting all the concepts of conventional orthodontics. Several studies show that it is possible to intervene with craniofacial growth even in the order of 3-4 mm and it is possible to modify the direction of growth, hence the importance of early functional therapy (Fig. 17).

To all this, however, we must add a very important fact that, to correct a malocclusion means to create positive influence on the posture and therefore the sooner you intervene fewer will be the influences and the postural problems. It becomes very important to consider that the position of the jaw affects the position of the cervical

vertebrae and the tone of the paravertebral musculature. The anterior position of the head on the sagittal plane causes an excessive contraction of the masticatory muscles with consequent dislocation of the jaw upwards and backwards and reduction of the physiological articular space (Fig. 18). These conditions through the muscular chains of the neck and shoulder girdle, are transmitted to the shoulder and shoulder blade in turn the shoulders respectively raised while the shoulder blade is detached from the rib cage; all this affects the spine and the pelvis and in particular the large psoas muscle, which by contracting determines the elevation of the pelvis with postero-anterior rotation with consequent shortening

of the homolateral lower limb causing tensions and lumbosacral pains. Preventive orthodontics through elastodontic devices therefore represents an important step forward in the field of orthodontics in developmental age since it can solve most of the orthodontic problems transforming many of these cases into ideal occlusions under an aesthetic, functional and postural profile. In some cases, at the end of this therapy it is necessary to place brackets (for a short period of time) for minor adjustments, such as the rotation of the posterior teeth, the straightening of the upper canines, closure of the spaces, the leveling or torque of the incisors and the expansion of the maxillary arch.

## Bibliography

- 1) Hanke BA, Motschall E, Türp JC. Association between orthopedic and dental findings: what level of evidence is available? *J Orofac Orthop* 2007;68:91-107
- 2) Sun L, Wong HM, McGrath CP. Relationship Between the Severity of Malocclusion and Oral Health-Related Quality of Life: A Systematic Review and Metaanalysis. *Oral Health Prev Dent*. 2017;15(6):503-517
- 3) Jose Luiz Villaça Avoglio Dental occlusion as one cause of tinnitus Medical Hypotheses, Volume 130, 2019
- 4) Eric Leroux, Stéphanie Leroux, Frédéric Maton, Xavier Ravalec, Olivier Sorel Influence of dental occlusion on the athletic performance of young elite rowers: a pilot study *Clinics (Sao Paulo)*. 2018; 73:e453
- 5) Vanini, D'Arcangelo, Mastroberardino: Aesthetics, Function and Posture; Ediz. ACME January 2018
- 6) Letter to the Editor The evolution of research on occlusion and brain function *Journal of Prosthodontic Research* 61 (2017) 6-8
- 7) M.Casini, S. Esente, F. Panzera, R. Saggini, G. Sarti *Visione e Posture*
- 8) Porto De Toledo I, Stefani FM, Porporatti AL, Mezzomo LA, Peres MA, Flores-Mir C, De Luca Canto G. Prevalence of otologic signs and symptoms in adult patients with temporomandibular disorders: a systematic review and meta-analysis. *Clin Oral Investig*. 2016 Aug 10
- 9) Aranitasi L, Tarazona B, Zamora N, Gandía JL, Paredes V. Influence of skeletal class in the morphology of cervical vertebrae: A study using cone beam computed tomography. *Angle Orthod*. 2016 Aug 11
- 10) P.S. Stein1, R.J. Kryscio, M. Desrosiers, S.J. Donegan, and M.B. Gibbs Tooth Loss, Apolipoprotein E, and Decline in Delayed Word Recall *J Dent Res* 89(5):473-477, 2010
- 11) Margaritis Z. Pimenidis *The Neurobiology of Orthodontics*. Springer-Verlag Berlin Heidelberg 2009
- 12) Barrow GV, White GR. Developmental changes of the maxillary and mandibular dental arches. *Angle Orthod* 1952;22: 41-46
- 13) Baccetti T, Franchi L, Toth LR, Mc Namara JA JR. Treatment timing for Twin-block therapy. *Am J Orthod*. 2003; 73:221-230 PM
- 14) Mc Namara JA. Maxillary transverse deficiency. *Am J Orthod Dentofacial Orthop*. 2000; 117:567-570
- 15) Kendall F, Kendall McCreary E, *Muscles functions and tests with posture and pain*. Verduci Editore, 1985
- 16) Wheeler TT, McGorray SP, Dolce C, Taylor MG, King GJ. Effectiveness of early treatment of Class II Malocclusion. *Am J Orthod Dentofacial Orthop* 2002; 121: 9-17
- 17) Sinclair PM, Little RM. Dentofacial maturation of untreated normals. *Am J Orthod* 1985; 146-56
- 18) Gonzales HE, Manns A. Forward head postures: ... a conceptual study. *Skull*. 1996;14(1):71-80



Prof. Dr. Lorenzo Vanini